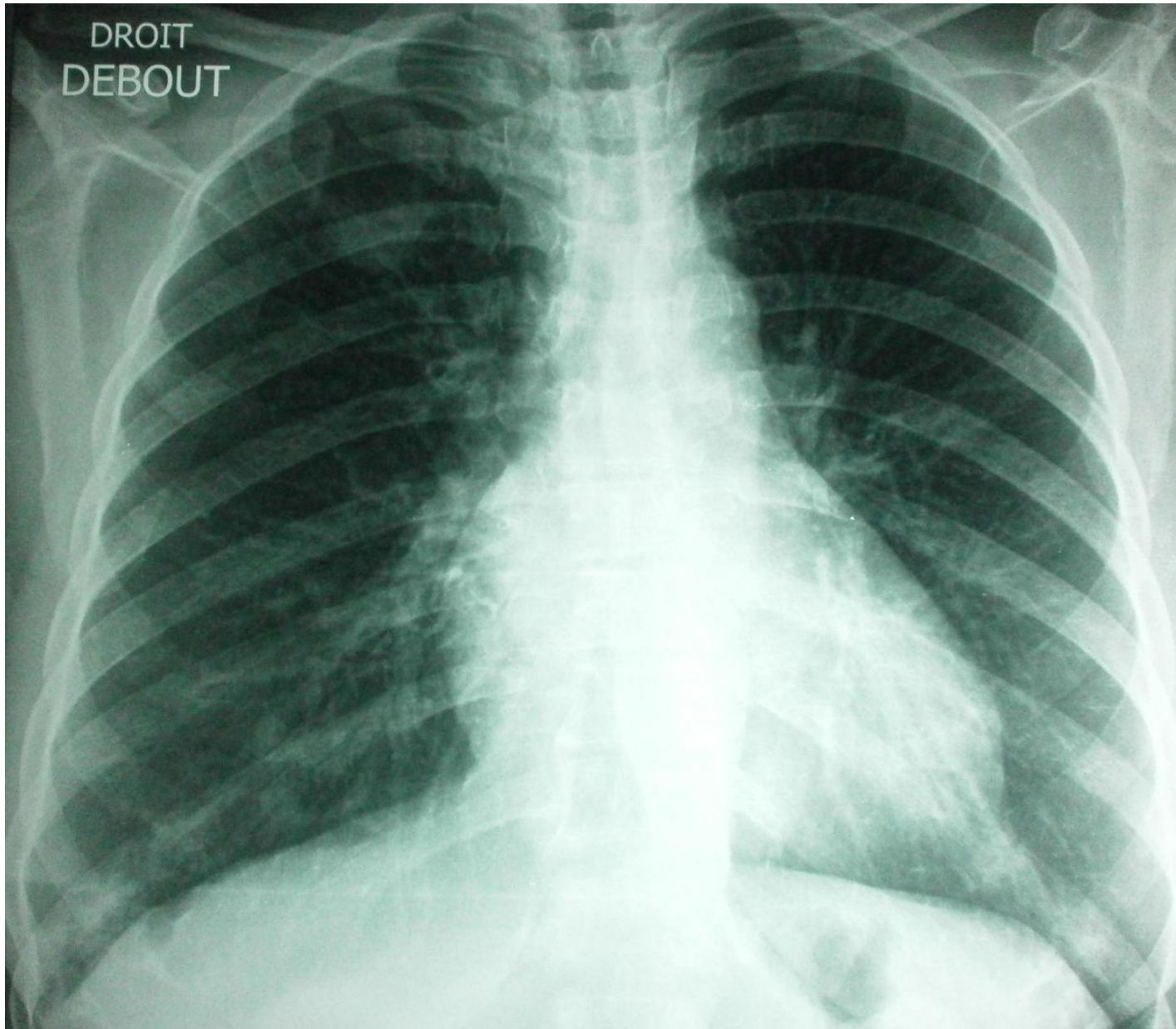
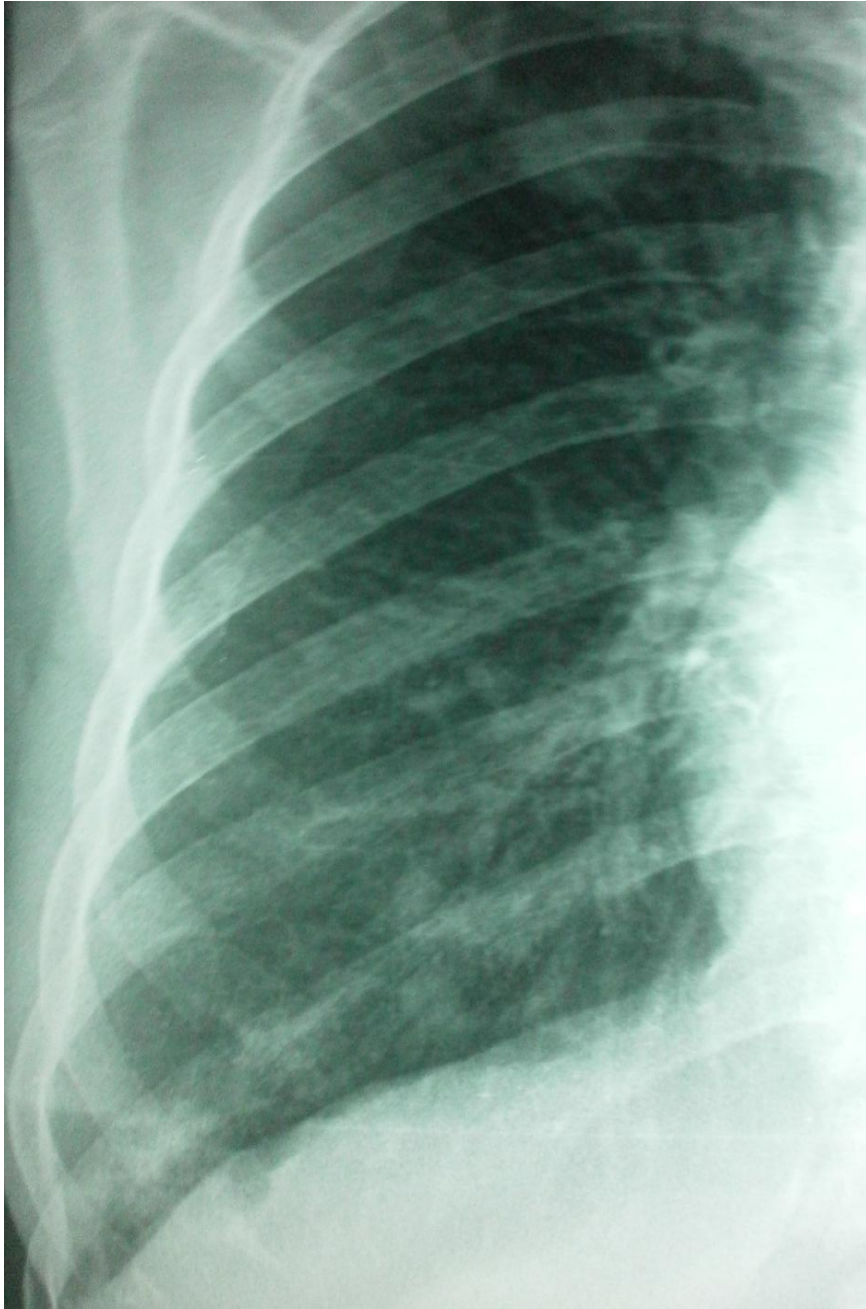
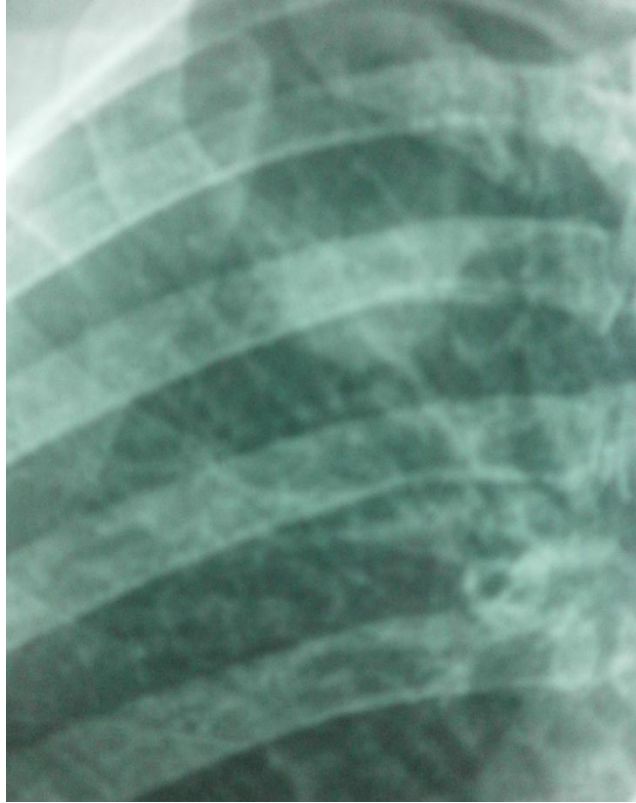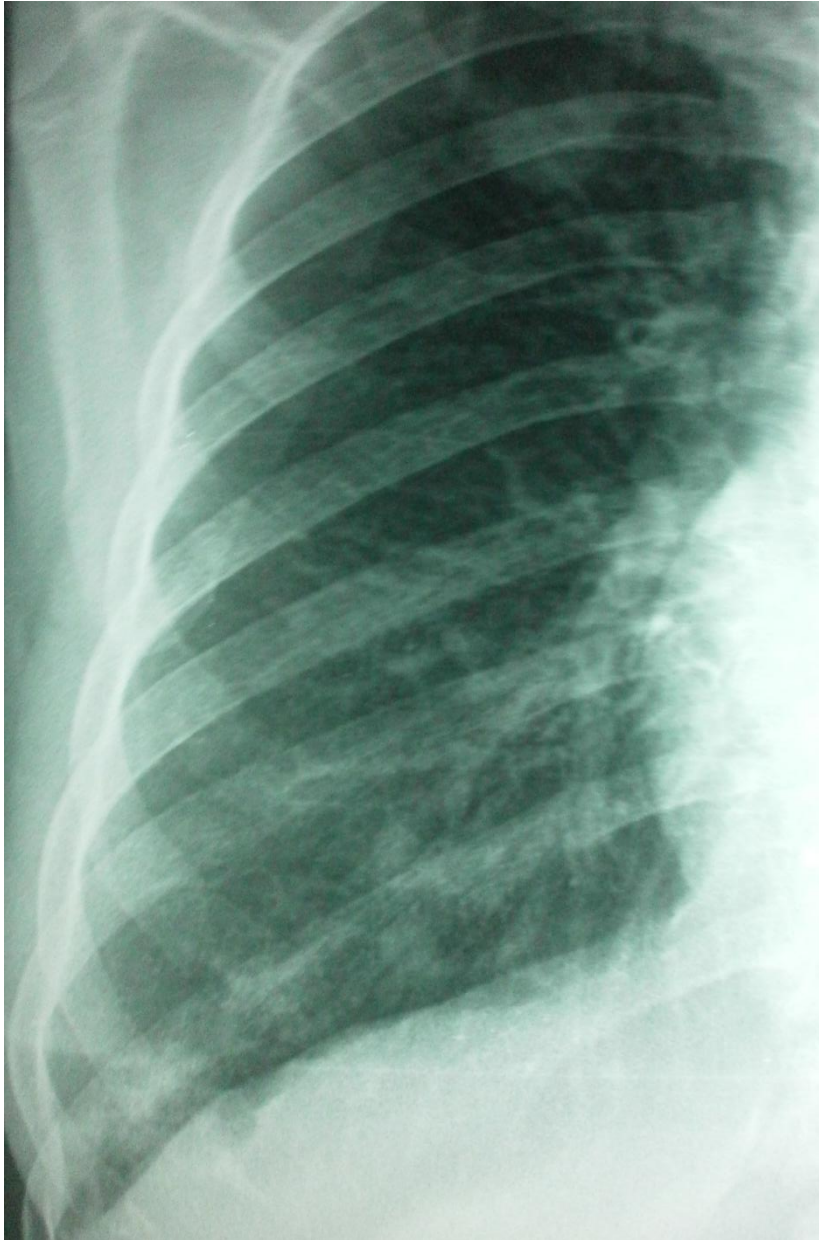
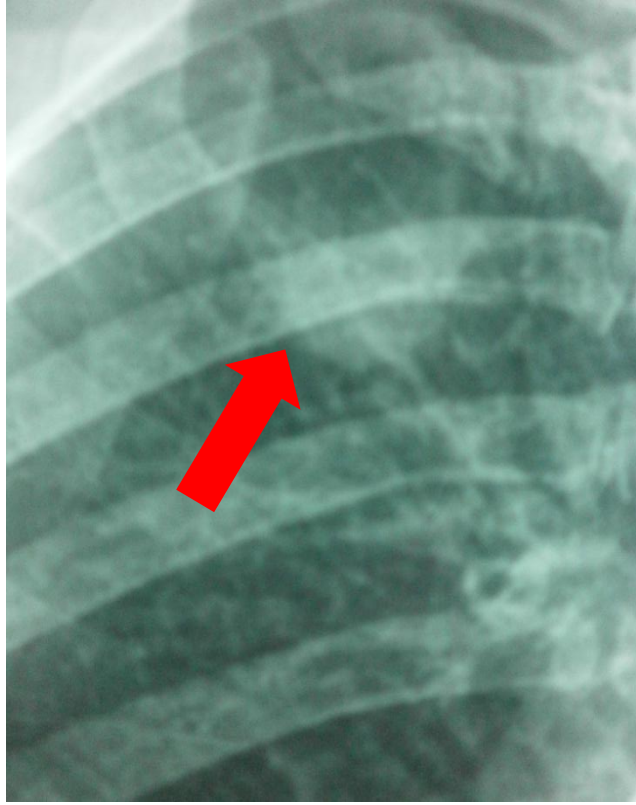
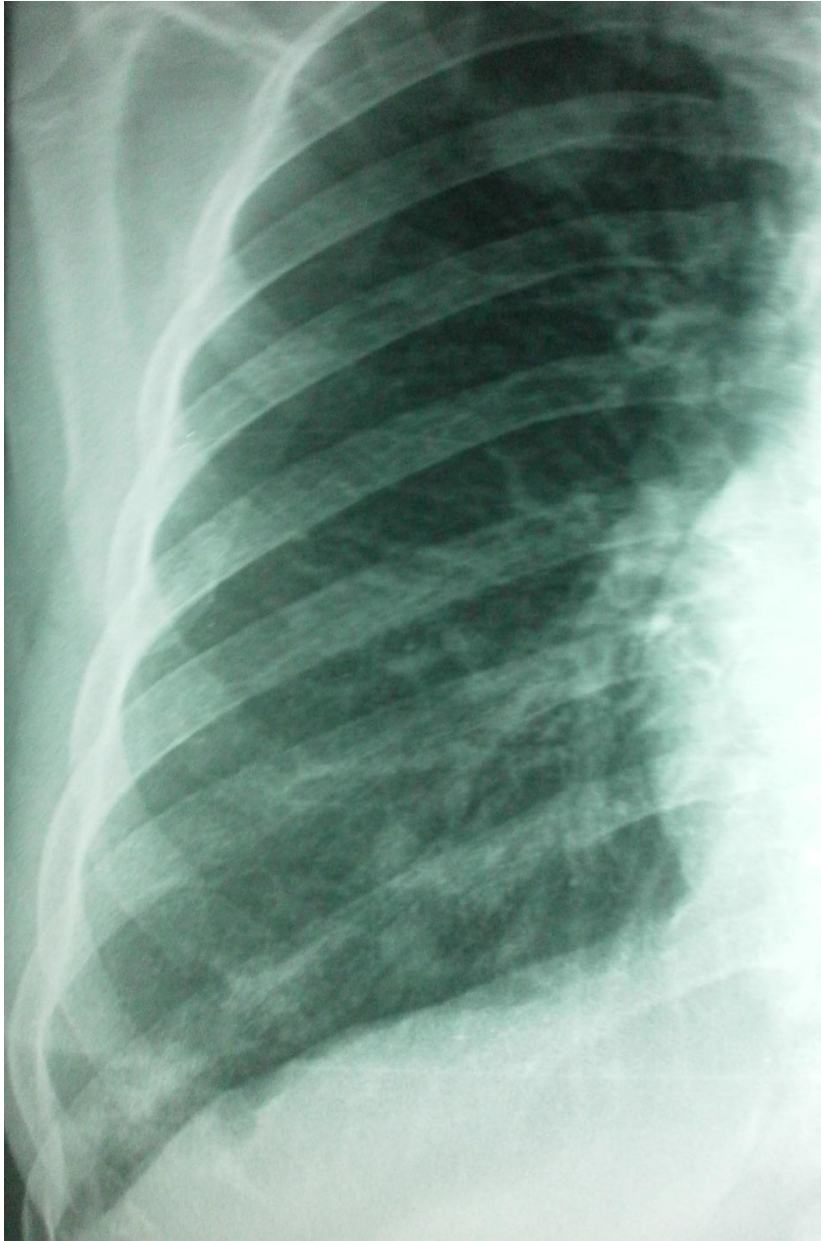


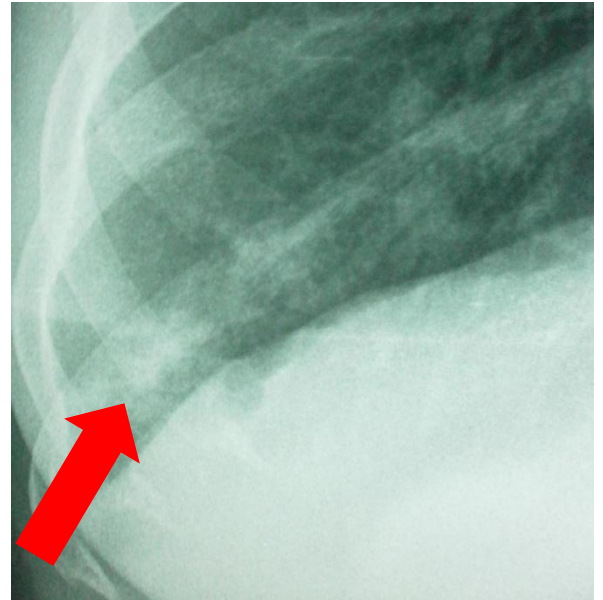
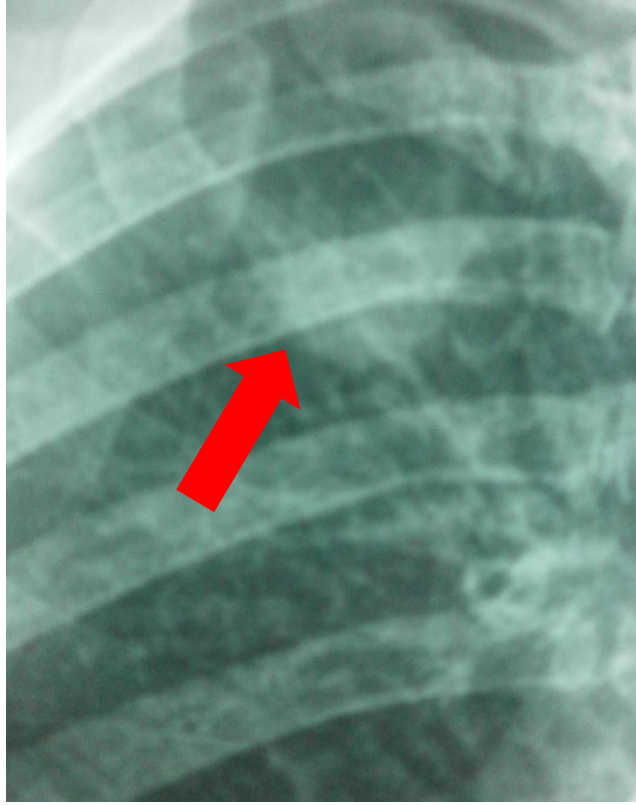
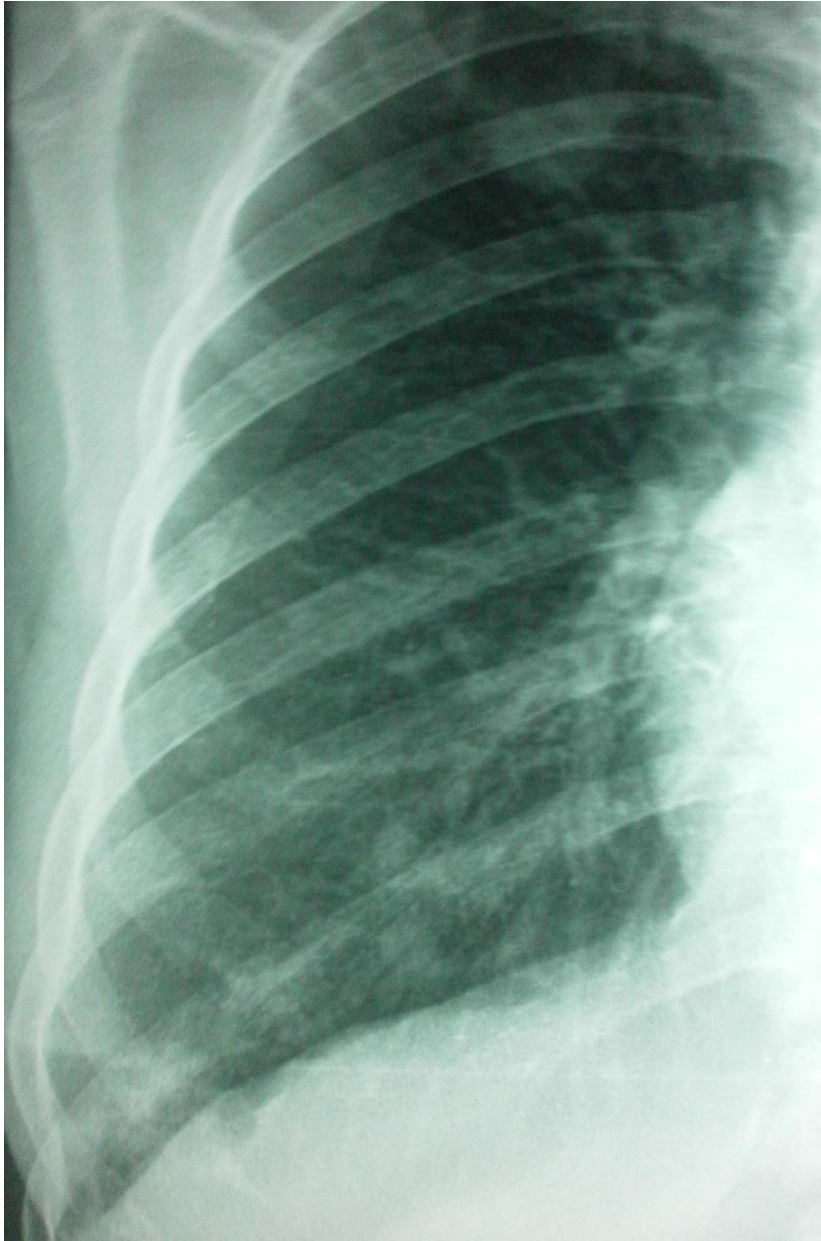
Mme Zina H..65 Ans .Elle tousse depuis 4 mois. VS 120/140











Scanner thoracique: Lacher de Ballon

